

Interventional radiology

Nonvascular

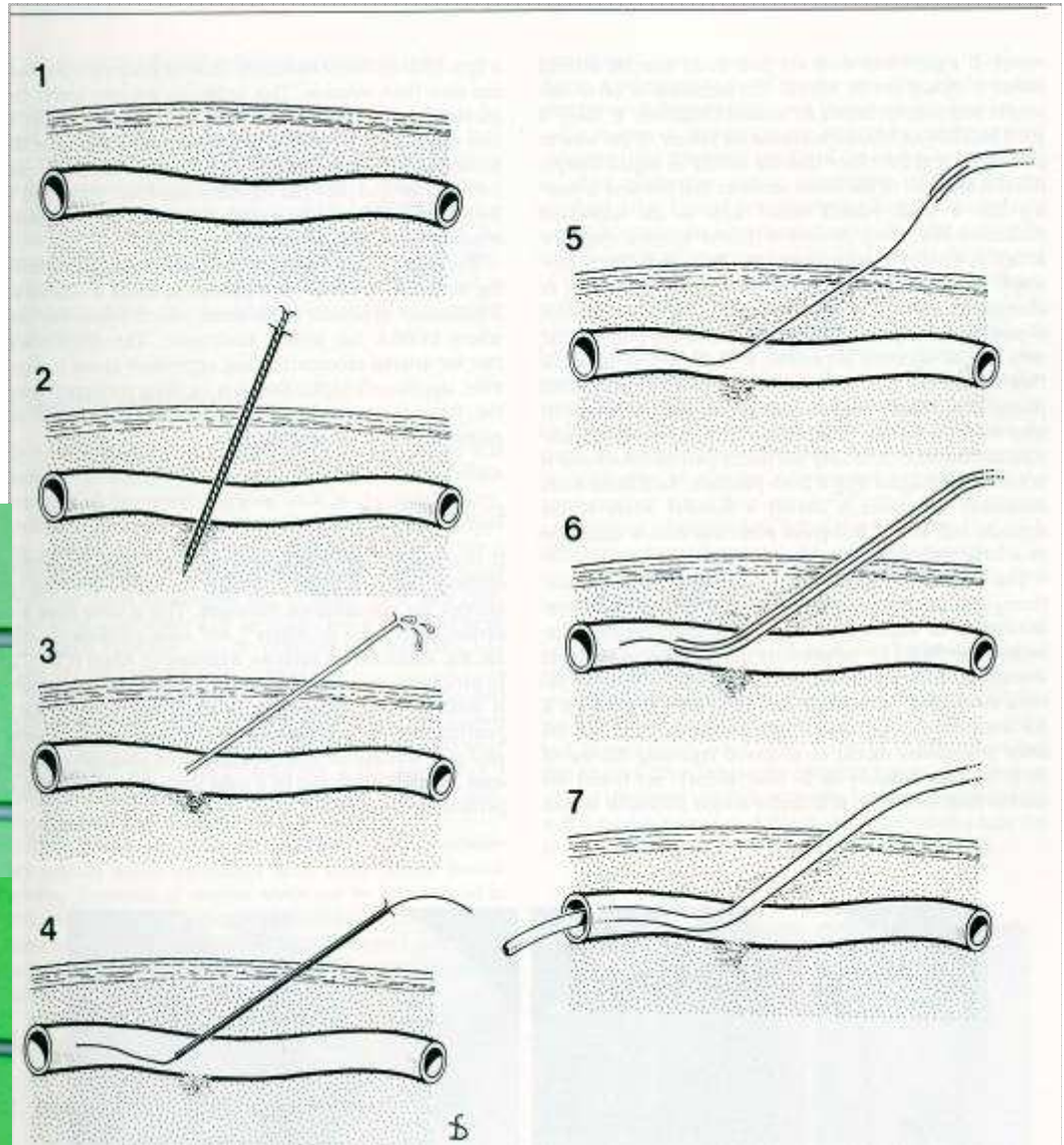
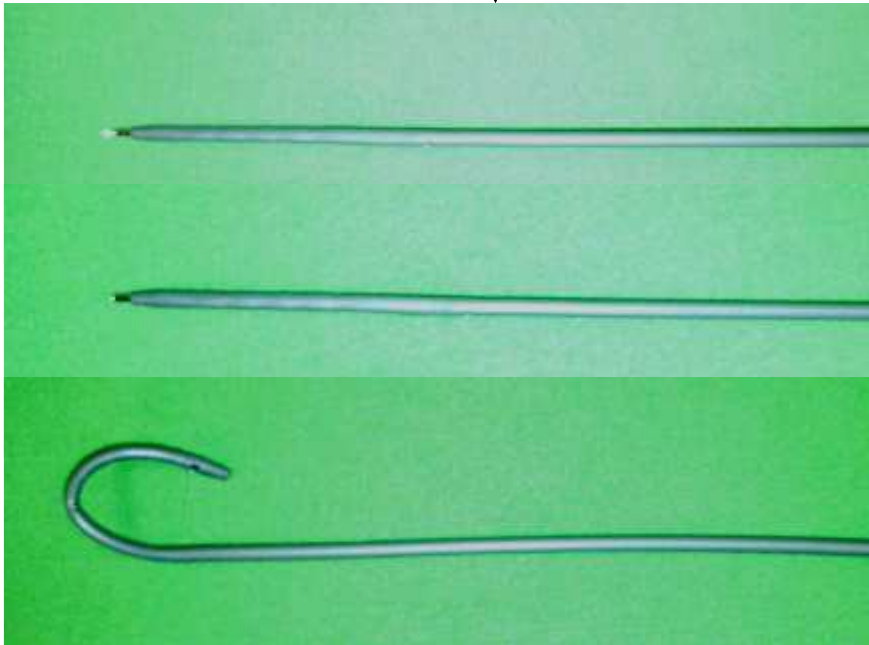
Doros Attila MD, Semmelweis Univ.
Dept.of Transplantation and Surgery
Radiology

IR/MIT

- Attempted non surgical invasive therapy with good results (sometimes as good as surgery), tolerated better by the patients. Sometimes the only way of treatment, palliative or curative.

Basic techniques (to enter the body)

- Seldinger →
- Trockar ↓
- Biopsy

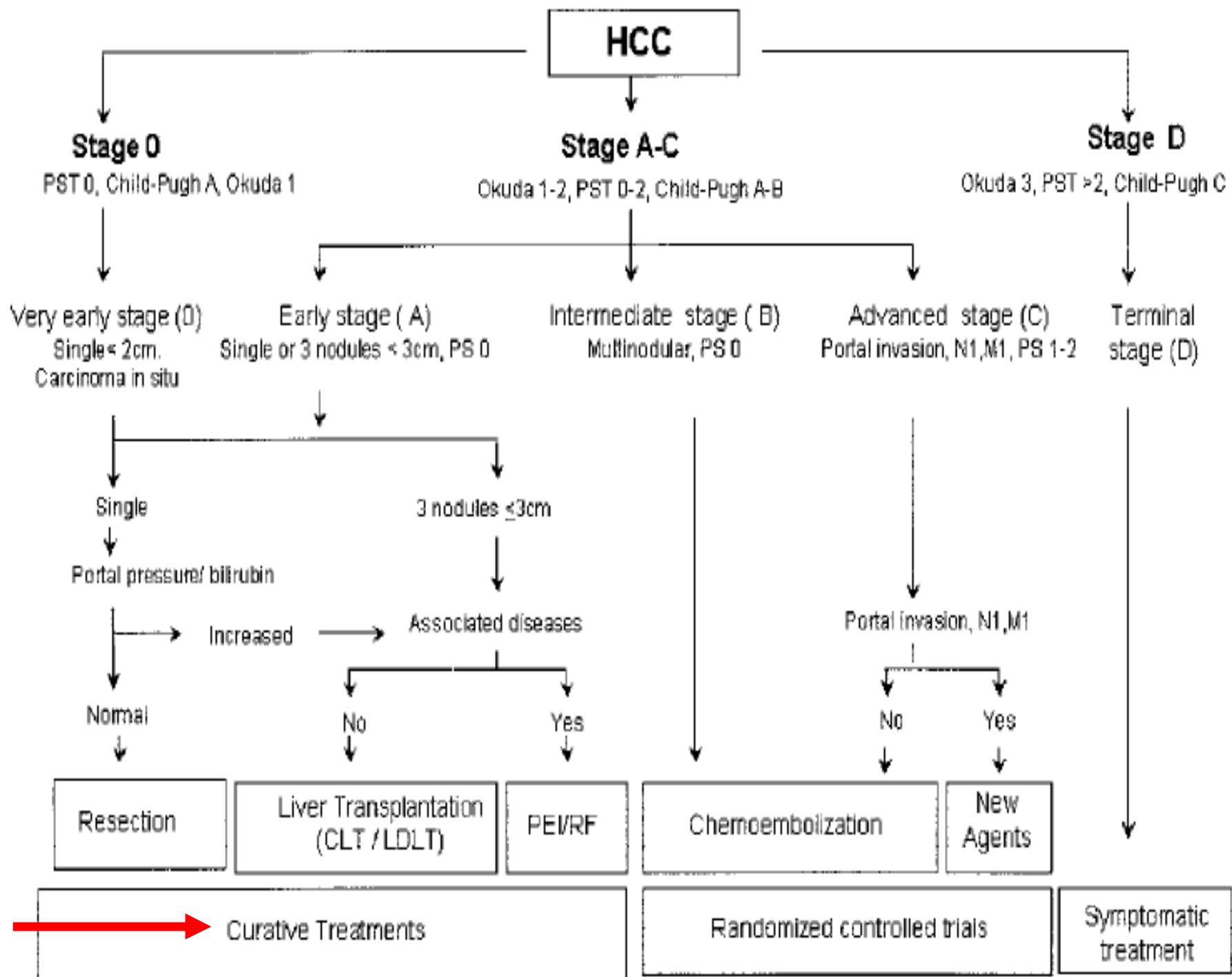


Biopsy

- Percutaneous sampling
 - Cells/cytology
 - FNAB/ 21-23G needles
 - Smear
 - Searching for malignity
 - Tissue/core
 - 14-20G needle
 - In diffuse or localised pathologies
 - (More complications)

Percutaneous ablative techniques

- Chemical
 - **Ethanol /PEI/** (acetic acid, *hot saline...*)/~3cm/
- Thermoablation
 - Cryo, laser, focused US, **RFA**
 - Appr.5-6cm max.diameter/session
 - **Liver, kidney**, lung, breast, **bone**
- Percutaneous, laparoscopic, open surgical
 - Combined



Clinical Complications

MAJOR COMPLICATIONS (2.1%)

- Intraperitoneal hemorrhage
- Intrahepatic hematoma
- Seeding
- Abscesses
- Hemothorax
- Diaphragmatic paresis
- Biloma
- Pneumothorax
- Portal hypertension
- Stenosis of common hepatic duct
- Venous thrombosis
- Multisegmental hepatic infarction
- Acute cholecystitis
- Septicemia

MINOR COMPLICATIONS (4.7%)

- Skin burn
- Asymptomatic thickening of gallbladder wall
- Self-limiting intraperitoneal bleeding
- Artero-portal shunt
- Thickening of diaphragm
- Subcapsular hematoma
- Biloma
- Intratumoral hematoma
- Pain

RENAL CC ABLATION

Best indication for RF

**Never seen recurrence in
treated area**

Low complications

Outpatient

RF Ablation of RCC

Initial Indications

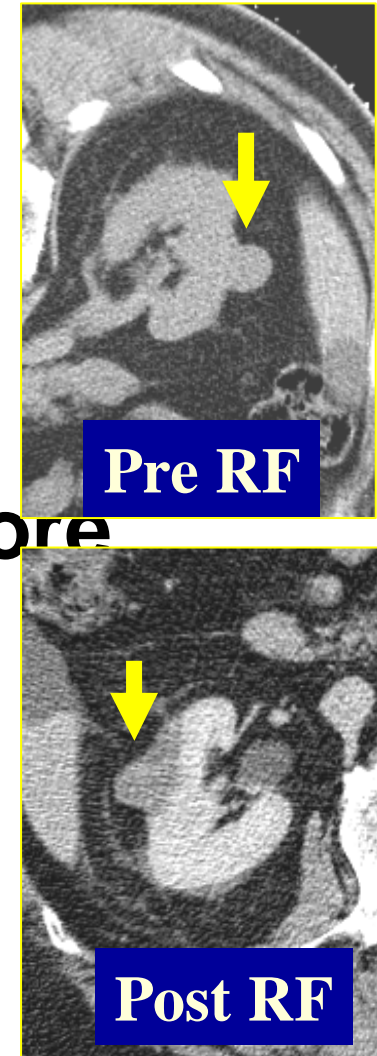
- Co-Morbidities, Poor Surgical Candidate
- Life Expectancy Less Than 10 years
- \pm Solitary Kidney
- No Evidence of Metastatic Disease

- **Expanded Indications**
- Palliation of large central tumors while maintaining renal function
- Hematuria Control

RF Ablation of Renal Tumors: Tumor Factors

Tumor Size

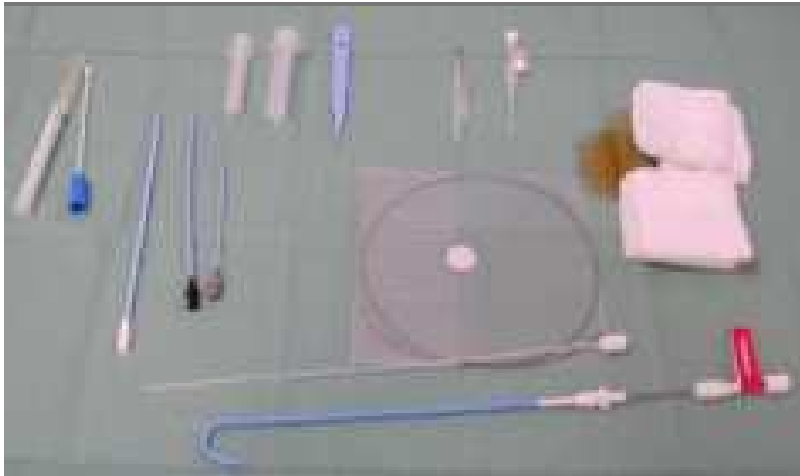
- **3 cm or less ideal**
 - 100% Technical Success
 - > 90% single session
- **3.0 - 5.5 cm can be done with more ablations; some more sessions**
 - 100% success if exophytic
 - ~ 70% single RF session



Aspiration/drainage

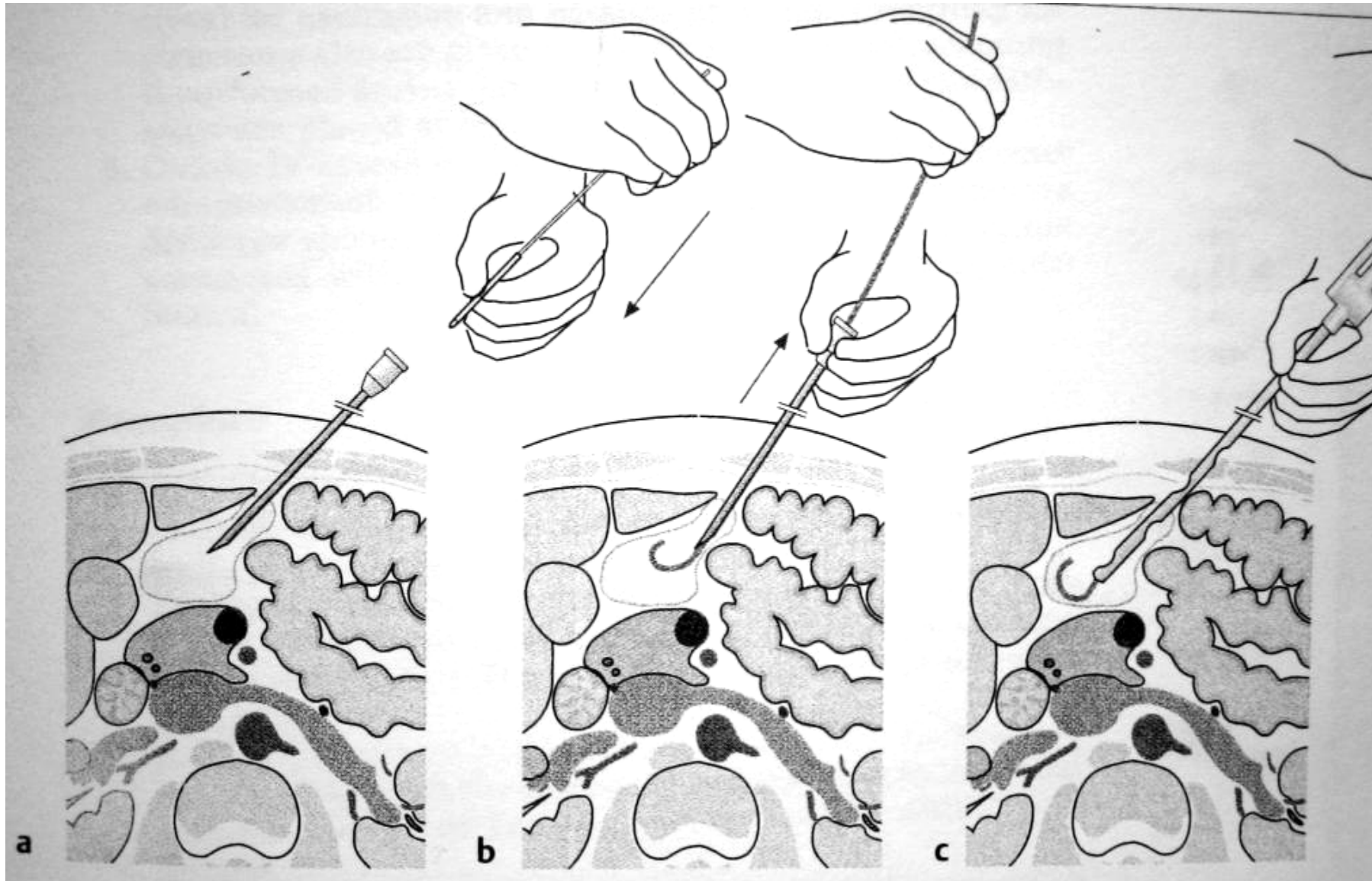
- Fluid collections, abscesses
- Diagnosis+therapy
 - Fluid aspiration, bacteriology, cytology
 - Drainage, lavage
- Depends on
 - Why we do it
 - The viscosity of the fluid
 - Safe access

Preparation

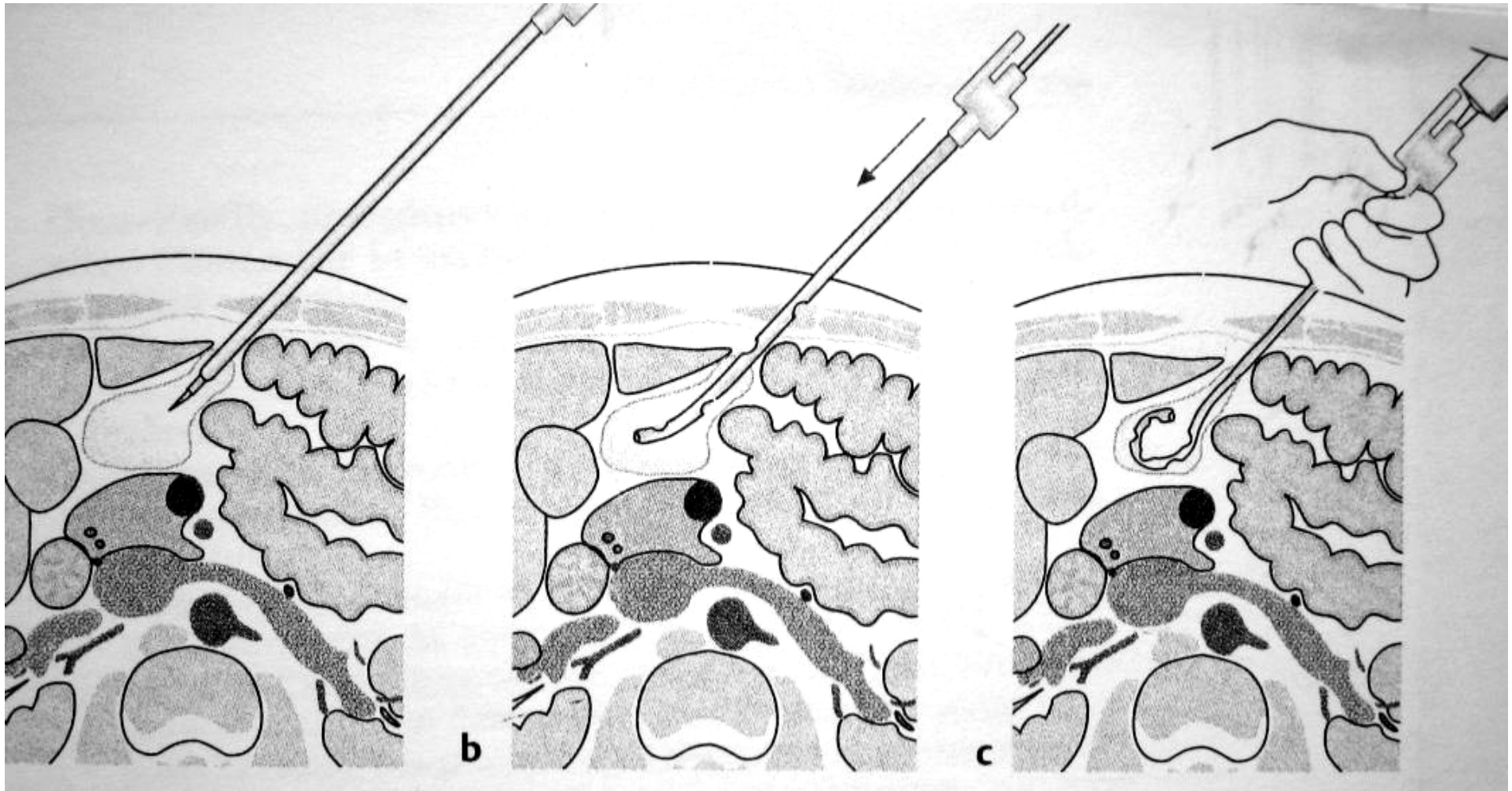


- Sedation
- Local anesthetic
- Puncture needle
- Guidewire
- Drainage catheter

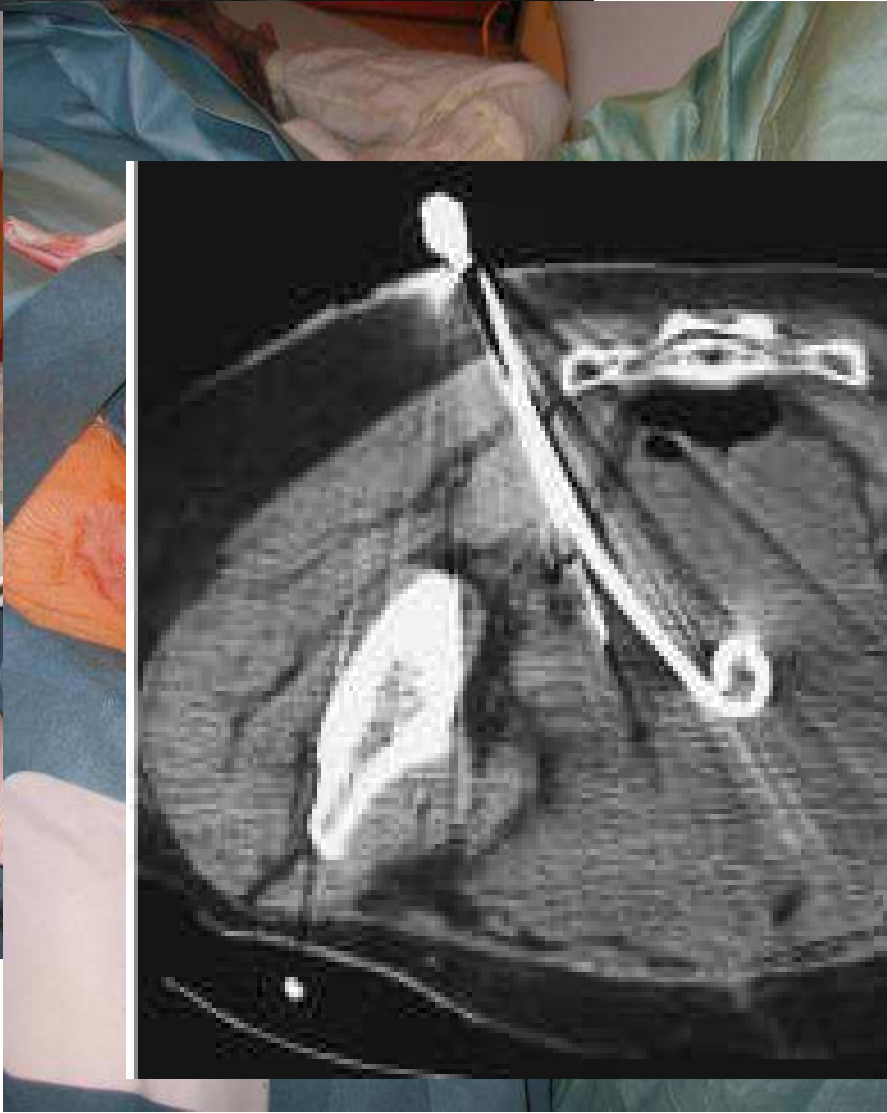
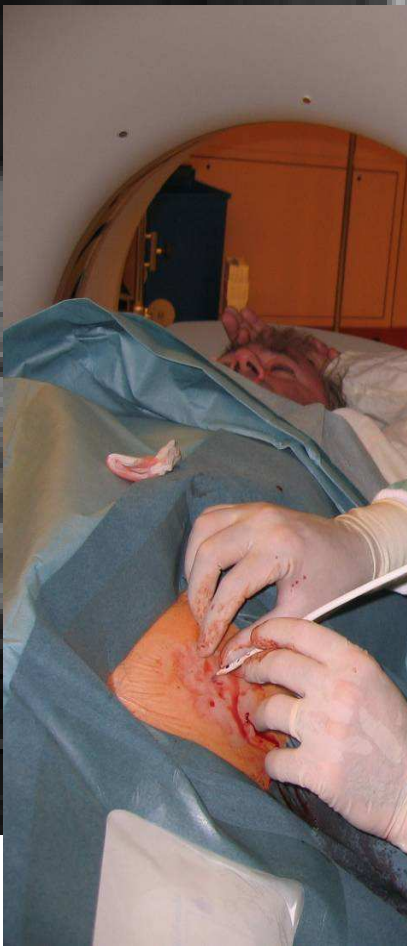Coaxial access



Trokar access



Trokar access



Aspirate evaluation

Bacteriogram	– Pus
Leukocytes, no germs abscess“	- „sterile
Creatinin	- Urinoma
Lymphocytes, fat	- Lymphocele
Bilirubin	- Bilioma
Amylase pseudocyst	- panc.

Sclerotherapy

- Cysta, lymphocele, seroma...
 - Percutaneous puncture, or drainage
 - The amount of the agent depends on the volume of the fluid in the collection
 - Alcohol
 - Betadine/braunol
- 20-30 min to be effective
- Aspiration of the sclerotizing fluid
- Repeat!

Biliary obstructions

- Cause can be
 - Stone
 - Stenosis/compression
 - Benign/malignant
- Therapeutic choices
 - Surgical
 - Endoscopic
 - Percutaneous (PTD: percutaneous transhepatic drainage, PTC: ~ cholangiography)

PTC-PTD

- US or fluoro guidance
- Transhepatic fine needle puncture of one dilated bile duct
- 0,018" initial guide wire insertion through the needle lumen
- 2 step coaxial dilatation of the tract (4-6F)
- Catheter/gw manipulation (0,035"gw)
- 6-10F drain, external/external-internal
- Stents

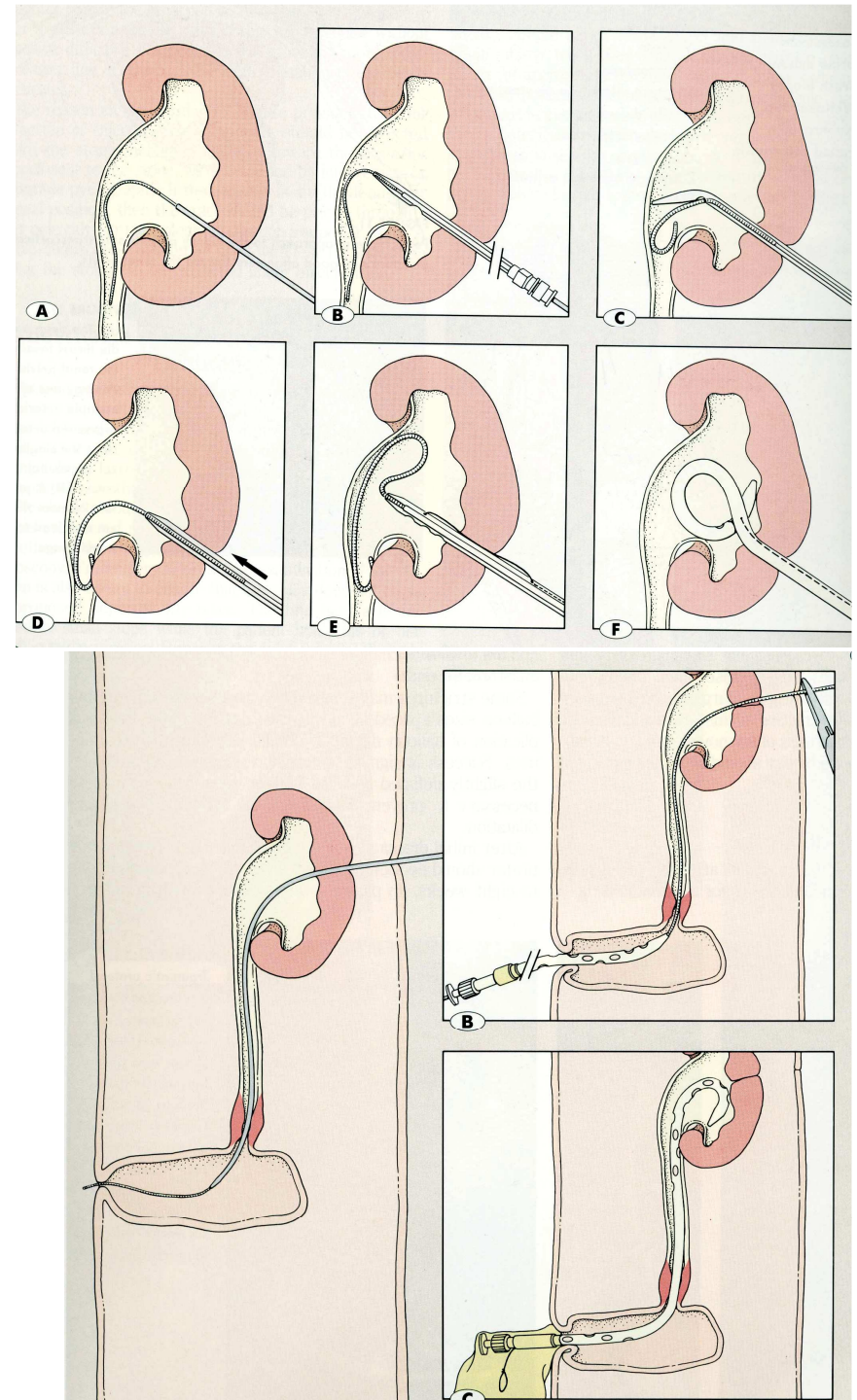
PERCUTANEOUS BILIARY INTERVENTION

Future changes

- MRCP will allow better selection of patients
- Endoscopic stents will be used in most patients
- Metallic biliary stents will be used in hilar strictures and endoscopic failures
- Biodegradable stents will have an important role in benign strictures

Uroradiology endourology

- Urine deviation
- Stone extraction
- dilatation
- ureteroplasty
- stenting
- Urology/radiology
 - Retrograde
 - Anterograde



Special interventions

- TIPS
- Shunt pta
- PVE
- Islet cell tx
- Hepatocyta tx
- GI-stents

GI-stents

- GI occlusion, when surgery not performed, due to the patient's condition, or technical factors
- Palliative stent placement
- 18-25 mm diameter
- OTW or endoscopic route
 - Min. 10F shaft – working channel

CIRSE /1

- PTA(percutaneous transluminal angioplasty)/stenting in lower limb
- Arterial thrombolysis
- Aortic stent graft
- Carotid stenting
- RAS (renal artery stenosis)
- Embolisation for GI bleeding
- AV-fistula management (dialysis shunts)

CIRSE /2

- Trauma
 - Management of injuries with IR techniques
- UFE (uterine fibroid embolisation)
- IVC (inferior vena cava)-filters
- Stroke (lysis)/neurointervention
- Coronarography (PTCA, stents)
- TIPS (transjugular intrahepatic portosystemic shunt)

CIRSE /3

- Venous access
- Venous intervention
- Musculoskeletal/ RFA (radiofrequency ablation), vertebroplasty, biopsy
- PVE (portal vein embolisation)
- Venous insuff. /ablation, sclerotisation
- Biliary interventions

CIRSE /4

- Oncotherapy
 - TACE (transarterial chemoembolisation), CP (chemoperfusion), RFA, PEI (percutaneous ethanol infiltration),
- RFA
- Abscess drainage
- Biopsy
- FNAB (fine needle aspiration biopsy)
- Robotics

This document was created with Win2PDF available at <http://www.win2pdf.com>.
The unregistered version of Win2PDF is for evaluation or non-commercial use only.
This page will not be added after purchasing Win2PDF.